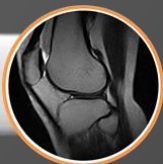

GREEN MRI

O·scan
Esote Dedicated MRI

MENOR...E MAIS PODEROSO

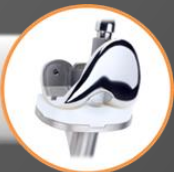IMAGENS



Dynamic



MAR



MERCADO DE RM



CONFORTO DO PACIENTE



INSTALACAO



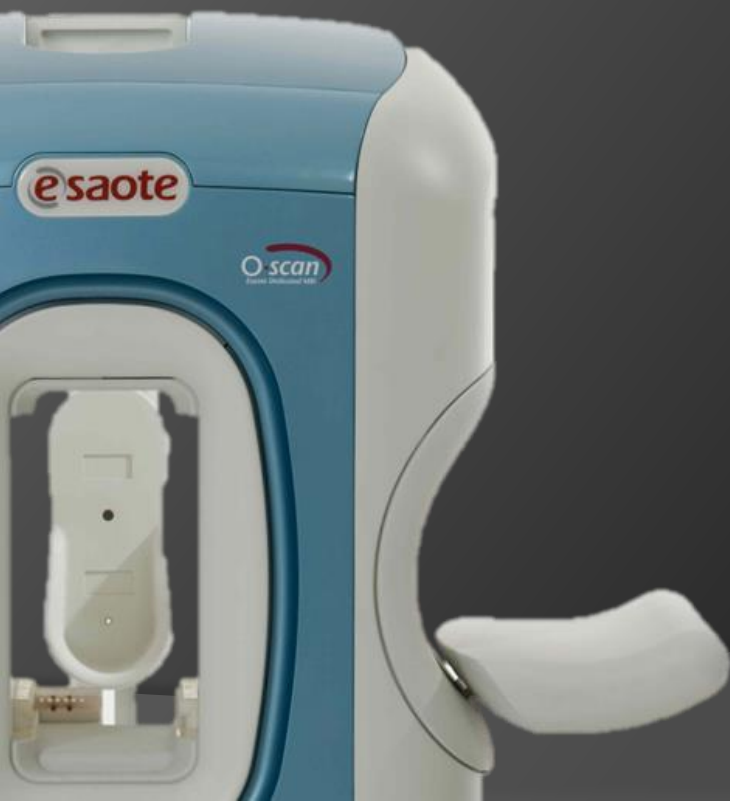ESTUDO CIENTIFICO



ASPECTOS ECONOMICOS

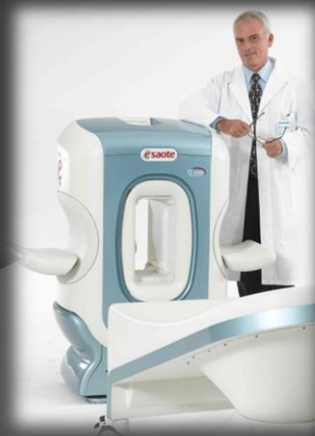

CENTRO DE REFERENCIA

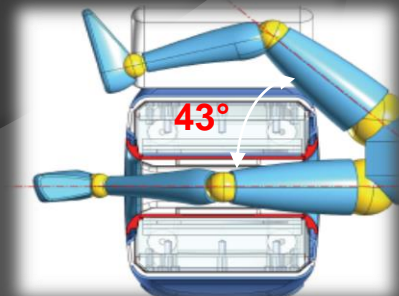
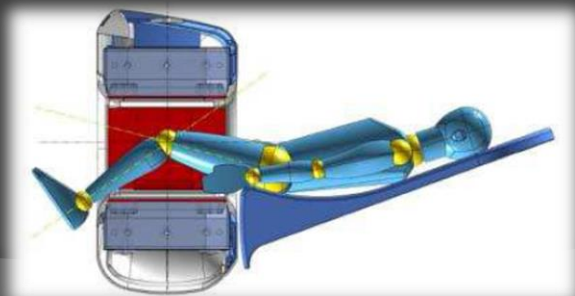
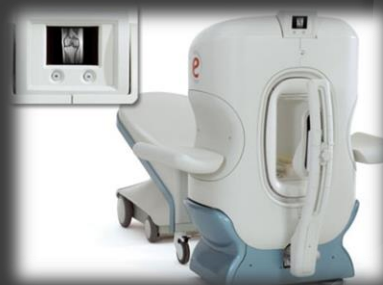
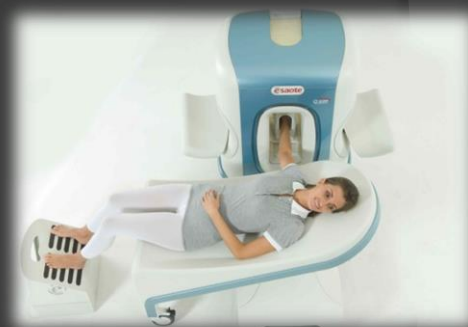
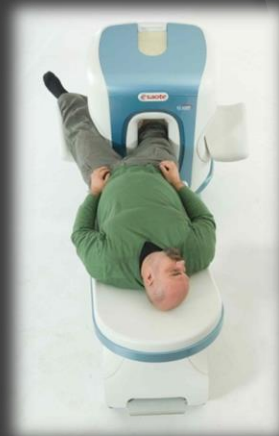esaote

- ✓ **O-scan** é uma RM dedicada específica para a área músculo esquelético. Cliente Alvo: Radiologistas, Ortopedistas e especialistas em Medicina do Esporte.
- ✓ **O-scan** é ideal para clínicas que desejam entrar no mercado com um equipamento de baixo risco econômico, alta qualidade e mínimo investimento.
- ✓ **O-scan** oferece a solução custo-benefício para grupos pequenos e/ou iniciantes de ortopedia/radiologia.
- ✓ **O-scan** é ideal para hospitais e clínicas que já possuem RM de alto campo com agenda saturada.



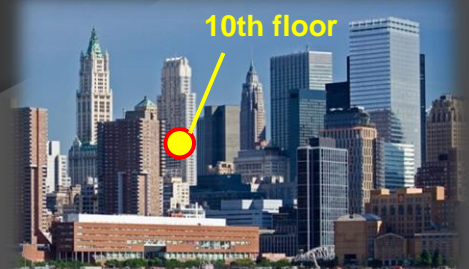
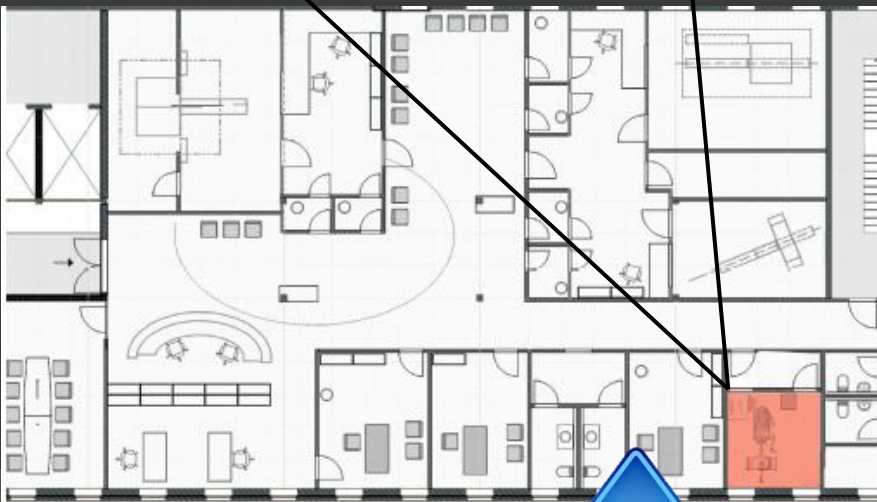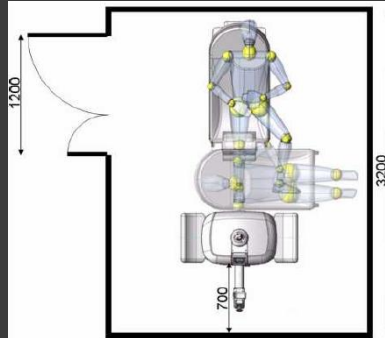
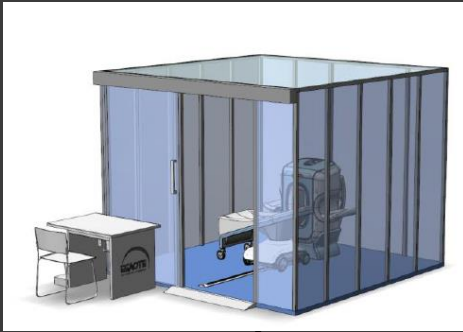
- ✓ Sem efeitos de claustrofobia
- ✓ Abertura do gantry de 18 cm para acomodar pacientes “grandes”
- ✓ Bobinas ergonômicas e gantry foram criados para aumentar o conforto do paciente durante o exame
- ✓ Painel de LCD para facilitar e agilizar o posicionamento (tempo real)



Dobre a capacidade da RM com a **O-scan**.

- ✓ Local: apenas 12m²
- ✓ Fácil instalação: nenhuma reestruturação; sem criogenia
- ✓ Plug&Play: 110/220V; coloque na tomada e comece a fazer exames

=== *Everyone can install O-scan everywhere!* ===



On the Effective Role of an Extremity-Dedicated MR Scanner in the Diagnostics of Trauma Patients



**UNIVERSITÄTS
KLINIKUM FREIBURG**

Radiologische Klinik

esaote

MIRDAC
MR development and application center

J. Bürk¹, P. Dovi Akue¹, M. Benndorf¹, P. Lenz¹, P. Niemeier², M. Vicari^{3,4} und M. Langer¹

¹Dept. of Diagnostic Radiology, University Medical Center Freiburg, Freiburg, Germany

²Dept. of Orthopaedics and Trauma Surgery, University Medical Center Freiburg, Freiburg, Germany

³Esaote S.p.A., Genoa, Italy

⁴Dept. of Radiology, Medical Physics, University Medical Center Freiburg, Freiburg, Germany

* Contact: marco.vicari@uniklinik-freiburg.de

Introduction

Since 2012 an extremity-dedicated 0.31T MR scanner has been operating in the Radiology Department of the University Medical Center, Freiburg for the diagnostics of different orthopaedic, emergency- and hand-surgery issues. This compact MR scanner has been playing an „on-demand“ role in the clinical routine of our department, being always available „on-call“. Indeed, it has been providing immediate MR examinations of the extremities, sensibly reducing the waiting lists.

Motivation

The advantages of small-sized, low-field MR scanners, dedicated to the imaging of extremities, are the reduced costs for purchasing and maintenance, together with an easy installation in relatively small sites (1). Moreover, children and claustrophobic patients can benefit from the small size of such scanners (2), since only the body part under investigation must be inserted into the magnet, as shown in Fig.1. In addition, lower-field imaging is less affected by susceptibility artifacts (3). On the other hand, the clinical protocols of low-field scanners need to be carefully optimized in order to try to get round the reduced SNR and CNR in comparison with 1.5T or even higher-field imaging (4).

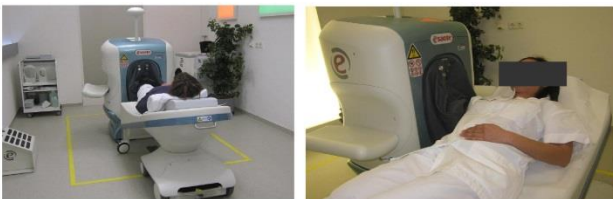

Fig. 1: Typical examination setup for extremities: only the body part to be investigated is positioned inside the magnet.

Materials and Methods

All patients were examined by a 0.31T extremity-dedicated MR scanner (O-Scan, Esaote, Genoa, Italy). Gradient amplitude is ± 20 mT/m with a slew rate of 50 mT/m/ms. The system is endowed with three dedicated dual phased array RF receiving coils (hand, knee, ankle/elbow). Due to the lower operating field strength, standard fat suppression imaging is not available. However, clinically relevant water-imaging is provided by means of fat-water separation techniques, as shown in Fig.2a-b.

From January 2012 till March 2013 were recruited for this study

- ✓ 62 patients with knee lesions who also underwent arthroscopy;
- ✓ 28 patients with suspect of fractures, who also underwent CT.

Figs.2-3 provides typical examples of joint diagnostic imaging.

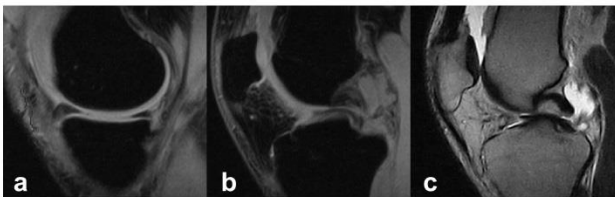


Fig. 2: Bucket-handle tear of the internal meniscus with a double rupture of the posterior cruciate ligament, coming along with articular effusion.

a-b: two water-imaging views of the X-BONE sequence (TR = 940 ms, TE = 11 and 22 ms, Flip Angle = 90°, FOV = 180*180 mm², M = 256*192, TH = 3,5 mm, TA = 5*48°);
c: FSE T2 (TR = 4920 ms, TE = 100 ms, FOV = 180*180 mm², M = 240*220, TH = 3 mm, TA = 4*25°).

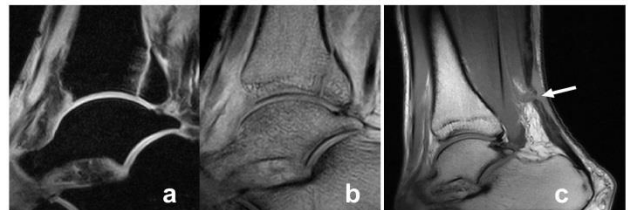

Fig.3: X-BONE water-imaging (a) and SE T1 imaging (b) of a tibia rear-edge fracture. 3D SHARC imaging (steady state FID and echo MR sequence) of a rupture of the Achilles tendon (c: see arrow).

Results

- ✓ **Knee lesions.** By means of knee arthroscopy 24 tears of the internal meniscus (IM) were diagnosed, including 8 bucket-handle tears (IM-BH), 15 tears of the external meniscus (EM), including 5 bucket-handle tears (EM-BH) and 31 ruptures of the anterior cruciate ligament (ACL). On the average, arthroscopy was performed 35.8 days after MRI, with a standard deviation of 28.7 days and a total range from 0 to 108 days.
- ✓ **Fractures.** According with CT, 11 out of 28 patients showed fractures.

MRI was retrospectively and independently analyzed by two long-term experienced readers. In comparison with arthroscopy for the knee lesions and with CT for suspected fractures (gold standards) the sensitivity and specificity of MRI are shown in Tab.1. The evaluation of the two readers did not show statistically relevant differences. All the ACL ruptures and all the fractures were detected by both readers. Moreover, 22 tendon complete ruptures (12 of the Achilles tendon, 3 of the quadriceps tendon and 7 of the biceps tendon) were effectively diagnosed by MRI.

	Sensitivity (%)	Specificity (%)
IM	98	99
IM-BH	100	99
EM	93	97
EM-BH	80	100
ACL	100	100
Fracture	100	100
Tendon Rupture	100	100

Tab. 1: Sensitivity and specificity of MRI. The gold standard for finding comparison was arthroscopy for meniscal lesions and CT for fractures.

Discussion

Low-field MR imaging has well-known limitations in terms of SNR and CNR (4). This notwithstanding, in the diagnostics of meniscus ruptures and cruciate ligament lesions several clinical studies have proved that low-field, extremity-dedicated MR scanners provide clinical reliability and efficacy comparable to those of middle- and high-field scanners (see e.g. Ref.5).

In our study several kinds of meniscus tears, cruciate ligaments and tendon ruptures, and joint fractures were readily identified with a very good sensitivity and specificity, thus confirming and extending what already reported. The FOV (a sphere of 14 cm diameter) was always large enough for the diagnosis of the above discussed lesions.

Conclusion

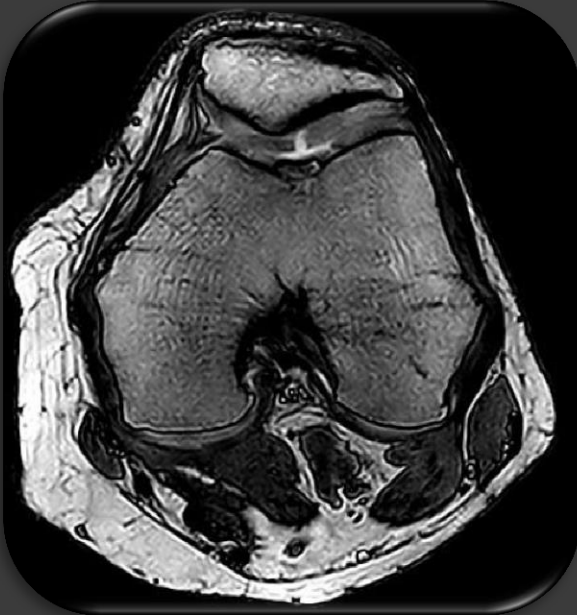The „on-demand“ scanner availability allows immediate extremity MRI examinations avoiding long waiting lists and assuring a prompt assignment of the required therapy. Both knee ligament lesions, fractures and tendon ruptures were effectively diagnosed. It follows that the extremity-dedicated 0.31T MRI scanner has proved to be reliable in the investigations of joints, with outcomes comparable to those of middle- and high-field scanners. Further advantages are the reduced costs for purchasing and maintenance.

References

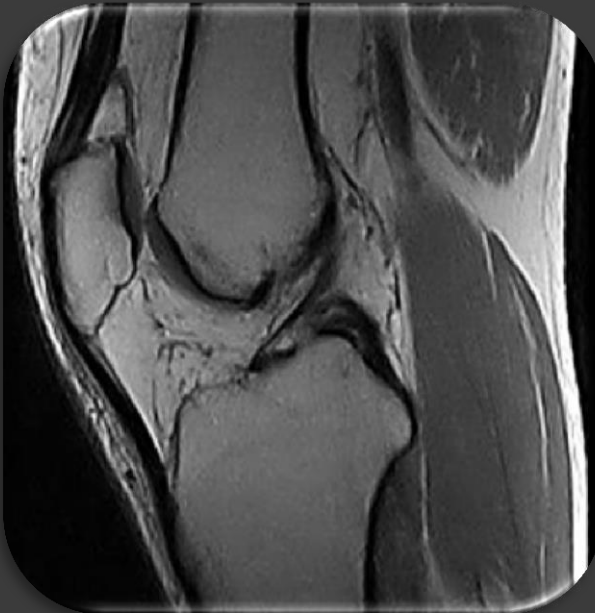
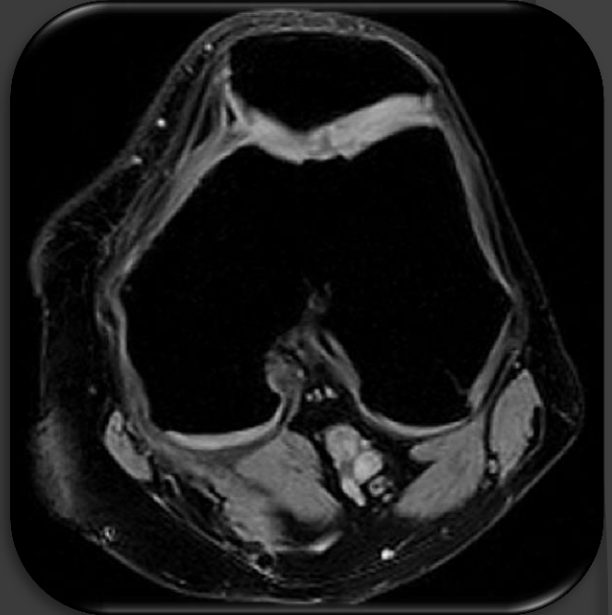
1. Hayashi N. et al., Magn Reson Med Sci 2004;3:27–38.
2. Ghazinoor S. et al., J Magn Reson Imaging 2007 Feb;25(2):234-4.
3. Matsuura H. et al., Neurol Med Chir (Tokyo) 2005 Aug;45(8):395-8, discuss. 39.
4. Maubon A. et al., Radiographics 1999;19:1057–1067.
5. Franklin P. et al., Am J Sports Med 1997;25:382–388.



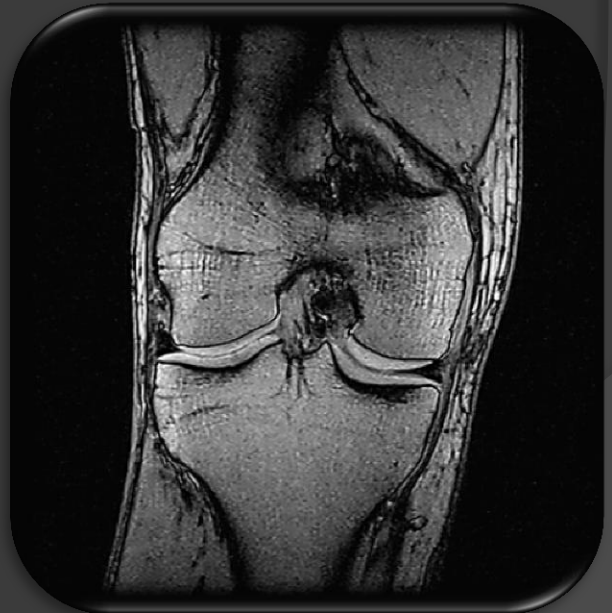
3D SHARC
Slice Thickness 0,6 mm



Xbone T2

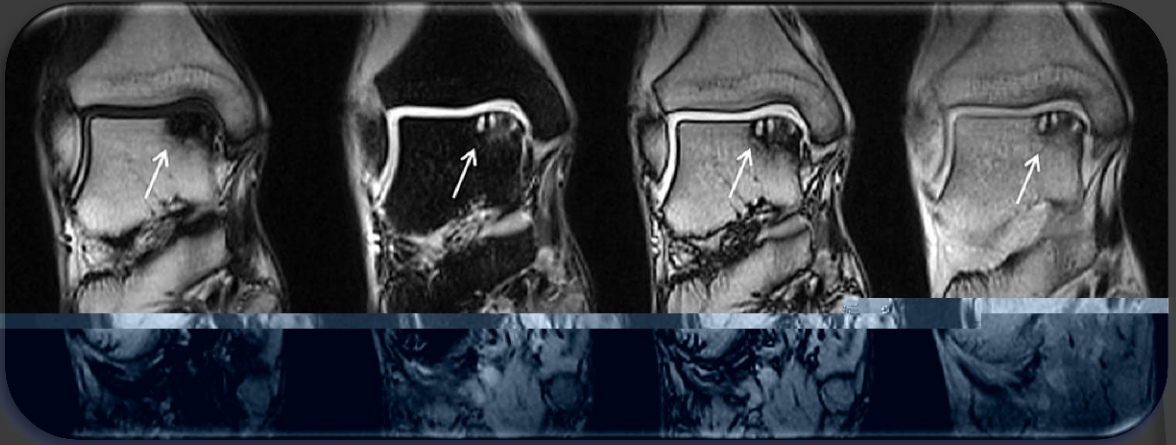


FSE PD

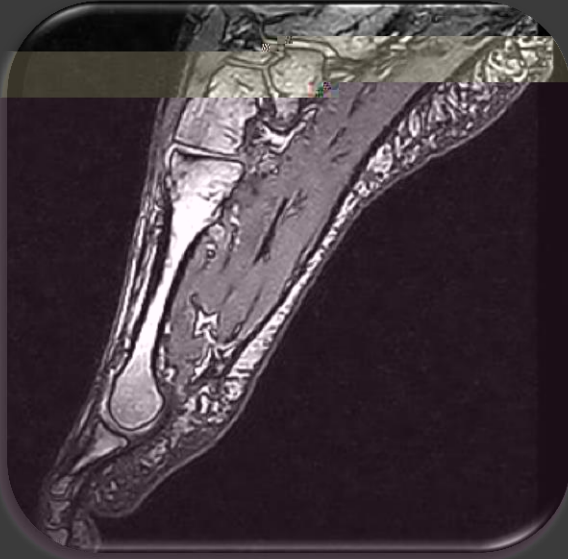

GE T1

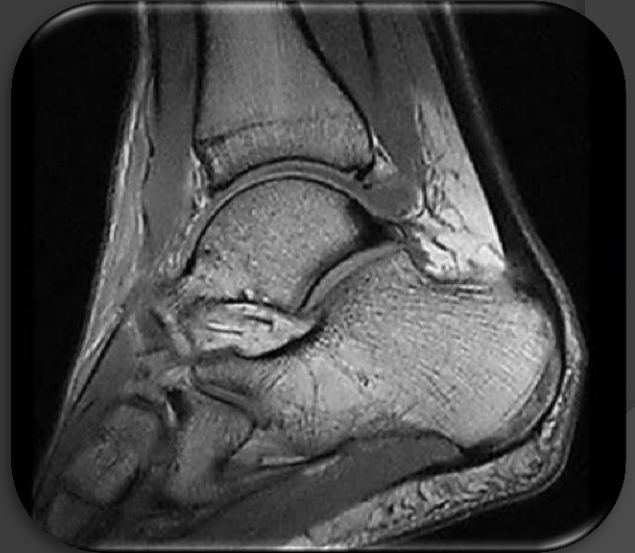



Xbone T2 – 4 echoes



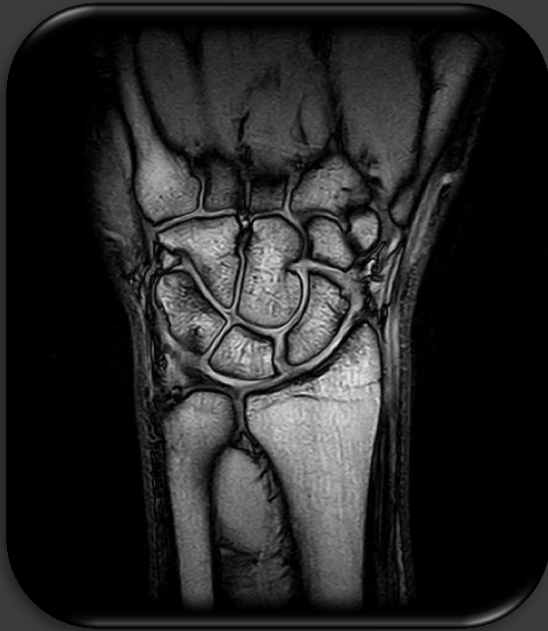3D SHARC
Slice Thickness 0,4mm



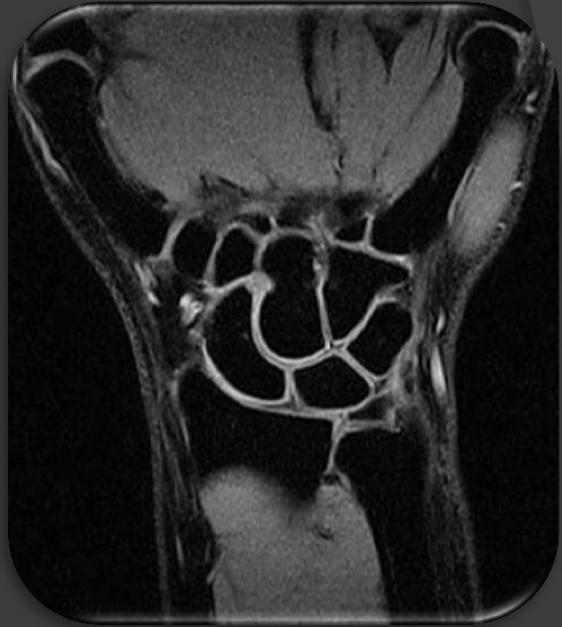SE T1



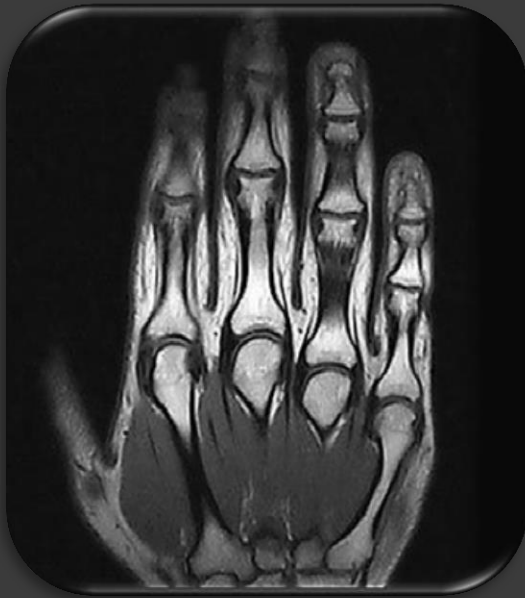GE T1



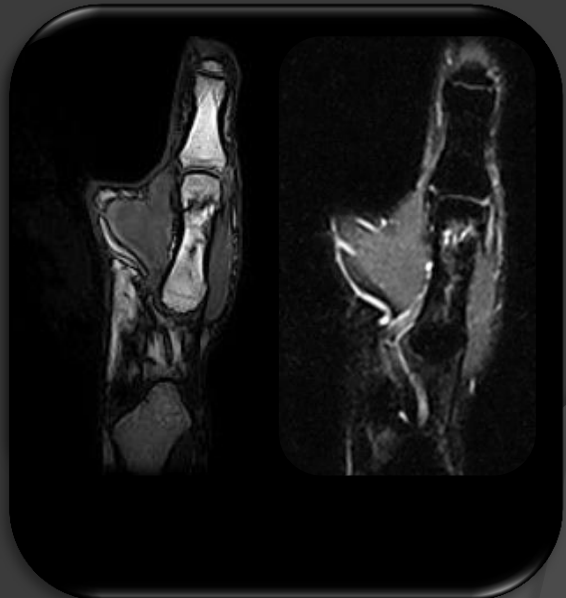
Xbone T2



SE T1



T3D T1



STIR

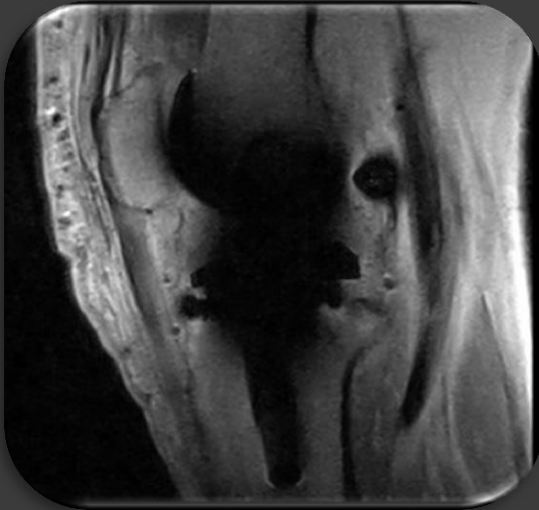

MAR

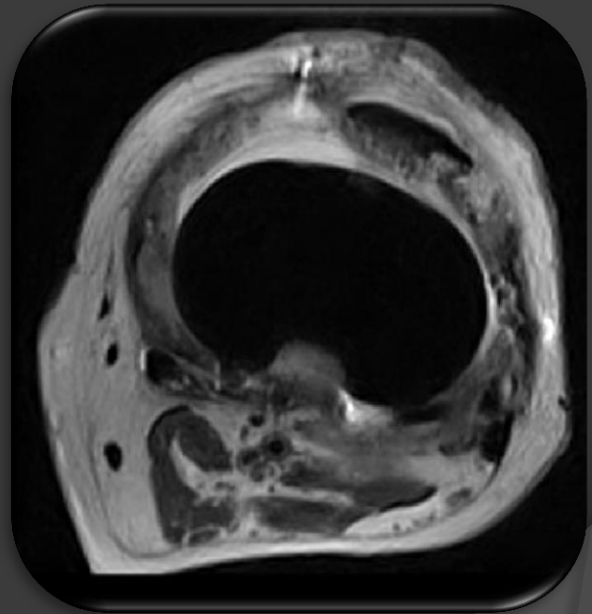
Metal Artifact Reduction

Reducao de artefato metalico

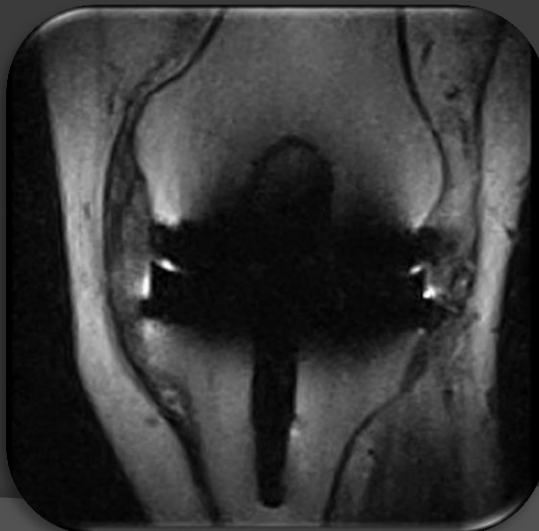
Os centros clinicos tem tido mais e mais demanda de exames pos cirurgico: com a tecnica MAR é possivel ter melhor detalhe e diminuir a distorção de implante metalico na estrutura anatomica para uma correta avaliacao de pos cirurgico da extremidade.



FSE PD

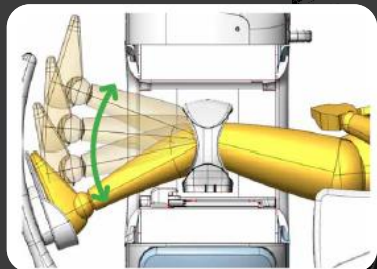


FSE T2



FSE T2



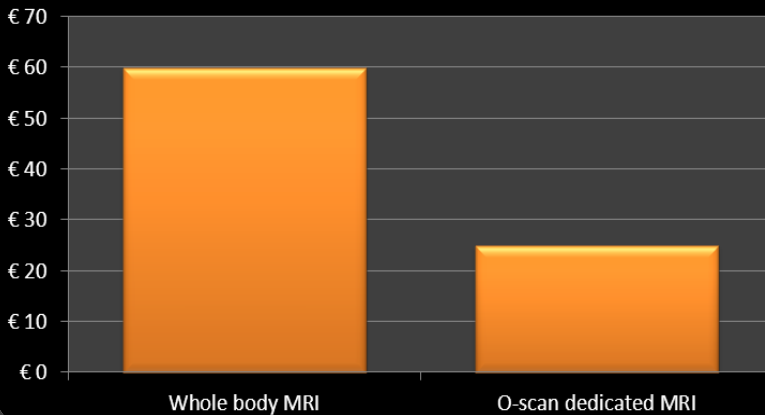


A abertura do sistema e ergonomia das bobinas da O-Scan possibilita fazer um exame de articulacao em movimento dinamico e funcional usando sequencias rapidas (2D HYCE streaming)



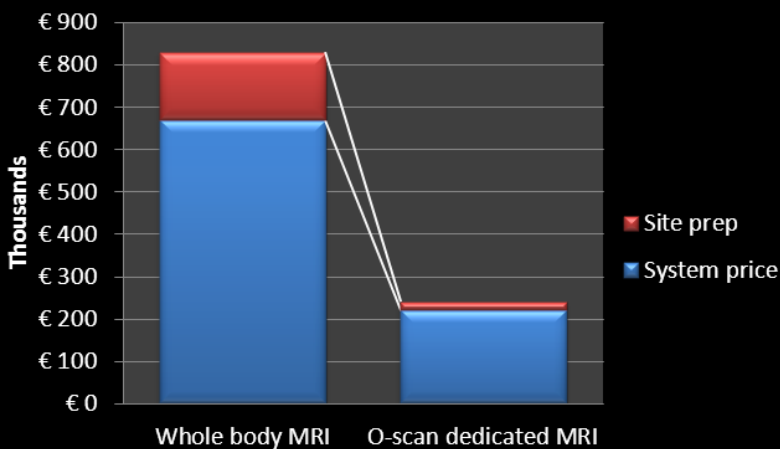
O-scan economics

Cost per exam*



*Assuming 30 exams per day

System purchase & Site prep



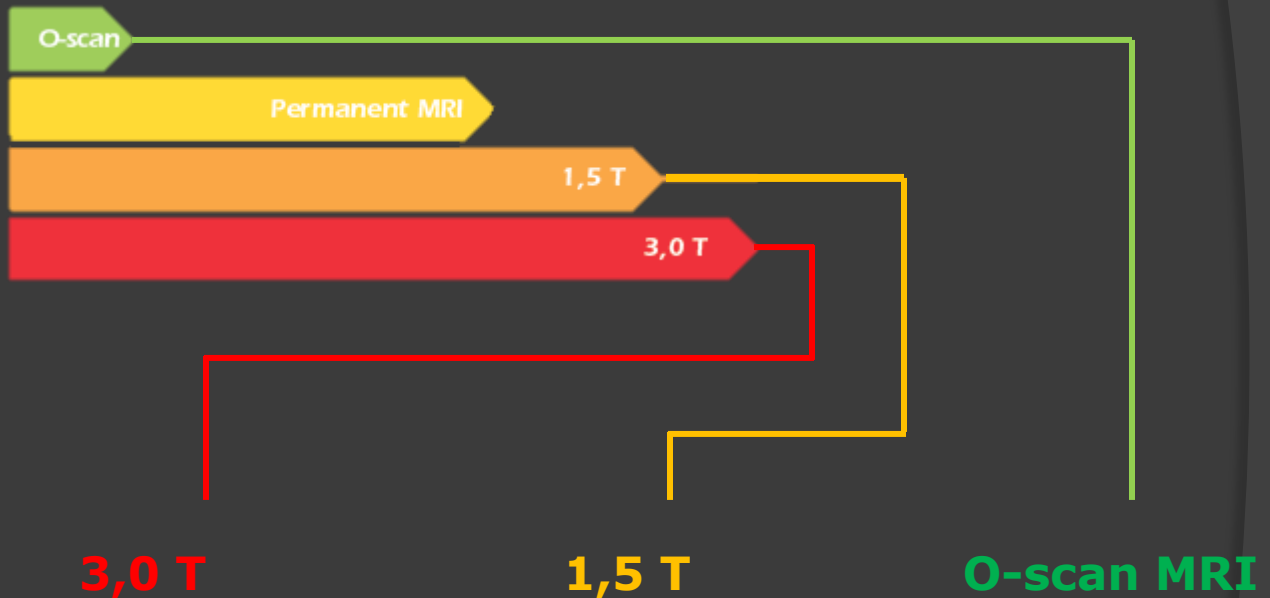
- Custos operacionais significativamente menores comparado a uma RM de alto campo.
- Ganho de **€ 200.000 por ano** comparado a RM de alto campo.
- Economia de **€ 40.000 anual** com gastos de energia elétrica

- Área de instalação otimizada
- Sistema Plug & play.
- Sem obras civis (*O-scan foi desenvolvida para entrar em elevadores e passar por portas comuns*).
- Sem criogenia (€ 35.000).
- RM compacta, espaço mínimo de 9m².



Comparação de consumo de energia elétrica/gastos entre Esaote O-scan RM e outros sistemas de RM.

Consumo Elétrico:



Consumo elétrico:
pode exceder 500.000 kWh.

Total de custos por ano: acima de **100.000.**

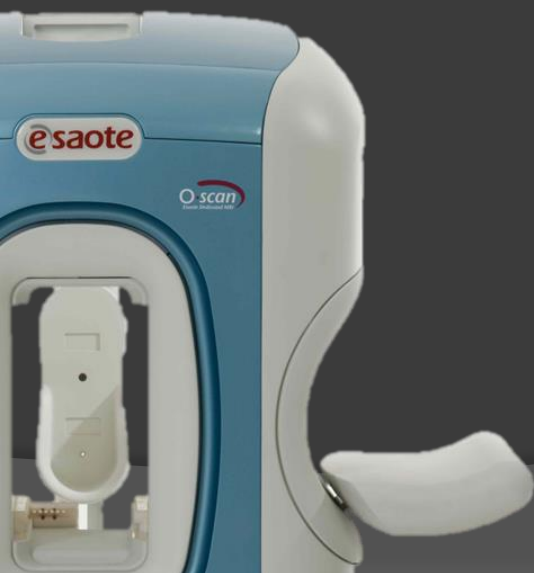Consumo elétrico:
entre 150.000 e 280.000 kWh.

Total de custos por ano: **entre 30.000 e 60.000.**

Consumo elétrico:
apenas 2000 kWh.

Total de custos por ano: menos que **1.000.**







Esaote MRI

Esaote: líder em RM dedicada
2500 RM instaladas no mundo

